

Clinical, microbiological and histological effects of cemented implant restorations.

A cross-over controlled clinical study

(Kliniska, mikrobiologiska och histologiska effekter av cementserad
implantat restaurering.

En cross-over kontrollerad klinisk studie)

Nadja Naenni, Sigrun Eick, Niklaus P.Lang, Christoph H.F.
Hämmerle, Björn Gjølvd, Jenö Kisch, Ann Wennerberg

Abstract

Aim:

The primary aim of this study is to test whether or not cement residues in the submucosal environment of implants lead to a change in the microbiota and induce inflammation of the periimplant tissues.

Material and Methods:

24 patients in need of a single tooth replacement will be enrolled in this cross-over controlled clinical study. All patients will receive a two-piece dental implant, which will be restored with both a cemented and a screw-retained single crown. At the time of impression taking, patients will be randomized into two groups.

Patients in group A will receive a screw-retained crown. Every 4 weeks microbiological samples using sterile paper points will be collected and analyzed for bacterial content by real-time PCR. Additionally, two host markers (MMP8, IL-1 β) will be determined by ELISA. Following this first period of 16 weeks, the screw-retained crown will be replaced by a new intraorally cemented crown. Cement removal will be preformed according to best clinical procedure. These crowns will again be left for another period of 16 weeks and followed up for the harvesting of microbiological samples every 4 weeks. After the second 16-week the crowns will be removed to evaluate any excess cement. All patients will be fitted with the orginial screw-retained crown. Clinical parameters for inflammation and probing depths will be obtained after each 16 week-period.

In group B the crowns will be incorporated in a reverse pattern. During the first 16 weeks any possible cement residues will be removed according to best clinical procedure, while for the second period of 16 weeks patients will be fitted with a screw-retained single crown. Again, microbiological and clinical parameters will be

obtained at the same intervals as in Group A.

After the second 16 week period the screw-retained crowns will be (re-) inserted in all patients, single tooth x-rays taken and clinical baseline values obtained. Additionally, a soft tissue biopsy will be harvested at the time of insertion of the final screw-retained crown. Patients will be followed up for another 16-week period.

Results:

XXXX

Introduction

The relationship between dental restorations and periodontal conditions has been studied, and it has consistently been demonstrated that dental restorations may constitute a risk factor for the initiation and progression of marginal periodontitis (Bjorn et al., 1969, Than et al., 1982, Claman et al., 1986, Jansson et al., 1994).

Periodontitis is an opportunistic infection involving pathogenic bacteria in a susceptible host. The pathogenicity of the microbiota is determined by the composition of the biofilms (Haffajee and Socransky, 2005). Gram-negative strictly anaerobic micro-organisms, such as *Porphyromonas gingivalis*, *Prevotella intermedia*, *Fusobacterium nucleatum* sp., *Tannerella forsythensis* and *Treponema denticola* belong to the putative periodontal pathogens. Moreover, *Aggregatibacter actinomycetemcomitans* is occasionally found in significant numbers. Consequently the conversion of a health-associated microbiota predominated by gram-positive facultative cocci and rods to a gram-negative strictly anaerobic microbiota may initiate the disease process. Such conversions are commonly observed in the presence of biofilm retaining factors (Brunsvold and Lane, 1990, Nassar et al., 1995, Lang et al., 1983) such as calculus or overhanging restoration margins. Already half a century ago, the role of potentially harmful effects of imprecise dental restorations impinging on periodontal health have been described (Waerhaug, 1956).

In an experimental study with deliberately placed overhanging margins of overlays in human volunteers it was demonstrated that gingival inflammation resulted 2-4 months after the placement of such overlays (Lang et al., 1983) concomitantly with a significant conversion from a health-associated to a disease-associated microbiota

predominated by gram-negative anaerobic bacteria.

This gingival inflammation was reverted to health soon after removal of the overhanging margins and the replacement of the overlays by clinically perfect margins. Again, this happened in accordance with a shift of the gram-negative anaerobic microbiota towards a health-associated microbiota.

In a cross-over design the study was repeated and similar outcomes were reported. At the sites of the overhanging margins the predominant cultivable flora was determined using continuous anaerobic culturing techniques. When restorations with overhanging margins were *in situ* an increase in gingival index scores and a subgingival microbiota closely resembling that of chronic periodontitis was detected. The presumptive gram-negative anaerobic pathogens proportionally increased from a few percent (2-4%) to substantial proportions (> 25%). Following replacement of the restorations with clinically perfect margins, a microbiota characteristic for gingival health was re-established.

Clinically, an increase in gingival index scores was detected when overhanging margins were placed. Bleeding on probing always preceded the peak level of black pigmented gram-negative anaerobic bacteria. During the limited duration of the experiment, no loss of attachment was detected at any site using subtraction radiography. The microbiota observed at the filling sites with perfect margins first represented a gram-positive, predominantly coccoid and health-associated microbiota, while in the second half of the experiment, when restorations with overhanging margins were placed, the microbiota resembled that of a periodontopathic gram-negative anaerobic biofilm. Thus, a potential mechanism for the initiation of periodontal disease associated with iatrogenic factors had

convincingly been demonstrated (Lang et al., 1983).

Periodontal and peri-implant diseases represent opportunistic infections triggered by a gram-negative anaerobic microbiota (Mombelli and Decaillet, 2011, Haffajee and Socransky, 2005). Although the microflora around teeth is very similar to that around implants, differences on a histological level exist between the two entities.

(Shahabouee et al., 2012, Berglundh et al., 2011) Biofilm retaining factors such as calculus, overhanging margins and cement excess may contribute to the conversion of a health-associated to a disease-associated microbiota. While established for teeth, a similar association has not yet been demonstrated at implant-crown sites.

Peri-implant diseases consist of two recognized entities, peri-implant mucositis and peri-implantitis (Jepsen et al., 2015). The former may appear to be the precursor of the latter which is characterized by loss of alveolar bone around an osseointegrated implant (Berglundh et al., 2011, Heitz-Mayfield, 2008). However, the factors influencing the conversion of peri-implant mucositis to peri-implantitis are still unknown. As it has been observed that dental restorations that were inaccessible for oral hygiene practices resulted in an initiation and progression of peri-implantitis (Serino and Strom, 2009) implant reconstructions, respectively excess cement may act as a biofilm retaining factor similar to dental restorations, hereby triggering disease progression (Wilson, 2009, Staubli et al., 2016, Korsch et al., 2014).

Hence, the primary aim of the present clinical experiment is to test whether or not cement residues in the submucosal environment of implants lead to a conversion of a health-associated to a disease-associated microbiota and consequently induces

inflammation of the peri-implant tissues.

Additionally, histopathological evaluation of the soft tissues around both cemented and screw-retained reconstructions will be performed to determine whether there are differences regarding host responses at implant sites as compared to teeth.

Material and Methods

Ethical aspects

The protocol of this study will be submitted to the regional ethical committee for human research in Malmö, Sweden. Patients will be informed of the risks and benefits in participating in this study and consent forms will be signed.

All patients will receive a screw-retained single crown. The implant material as well as the reconstruction will be provided according to an existing fee while the implant installation will be charged regularly. Furthermore, regular annual recall visits with a dental hygienist will be scheduled for two years following the conclusion of the study.

Experimental subjects

From the patient pool of the specialist clinic (Folktandvården AB Skåne, Specialisttandvård, Lund, Sweden), 24 adult patients with single tooth gaps in the posterior region of either jaw (no antagonist needed) will be recruited. Patients have to be systemically healthy and eligible for implant placement.

Inclusion criteria:

- patient older than 18 years
- systemically healthy subject
- periodontally healthy individuals
- absence of peri-implantitis
- no bone loss
- good oral hygiene (PCR \leq 20%)
- healthy periodontal tissues (BoP \leq 20%)
- patients with a single tooth gap in the posterior area of either jaw
(premolars and molars)
- at least 8mm in mandible; at least 6mm in maxilla (summers technique)

Exclusion criteria:

- ongoing periodontal disease
- bruxism
- unwilling to comply with study procedures
- heavy smokers (\geq 10 cig/d)
- ongoing periodontitis/implantitis

Clinical procedures

All subjects will receive a thorough baseline examination including a patient history, an examination of all oral tissues encompassing tooth vitality, hard structures (caries), as well as gingival and periodontal tissues and a radiographic status. Depending on this examination the patient will receive a hygienic phase following which an oral

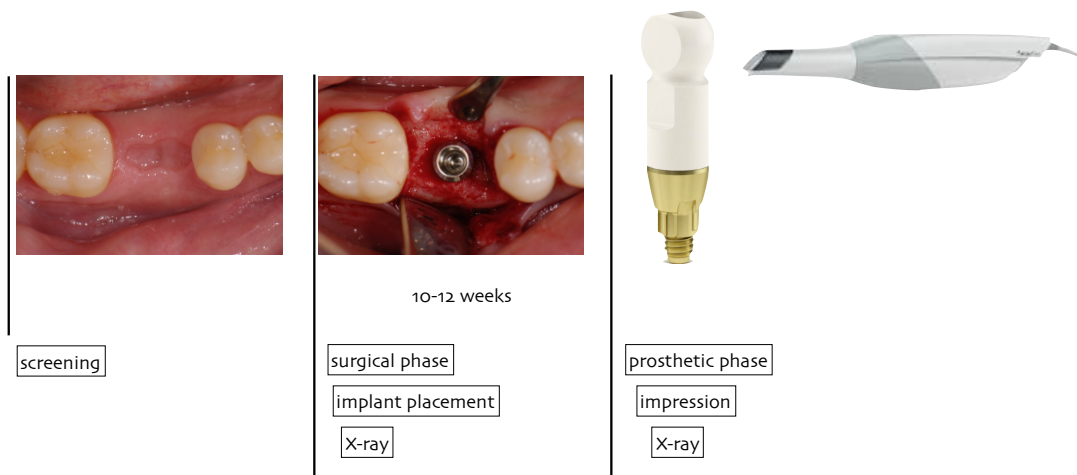
implant will be placed.

Surgical procedure

A two-piece dental implant (Astra EV, DentsplySirona Implants, Mölndal, Sweden) will be placed according to the manufacturers recommendation. The implant shoulder will be placed flush with the bone. In cases of minimal soft tissue thickness it may be placed subcrestally in order to allow for the biological width to be established. Before suturing the soft tissue thickness will be measured with a calibrated periodontal probe (UNC 15). After primary wound closure a periapical radiograph of the implant site will be obtained. Following a period of submerged healing of 10-12 weeks, abutment connection (AC) will be performed, soft tissue measured with a periodontal probe (UNC 15 with a point diameter of 0.4mm) and a standardized healing abutment (DentsplySirona Implants, Mölndal, Sweden) inserted.

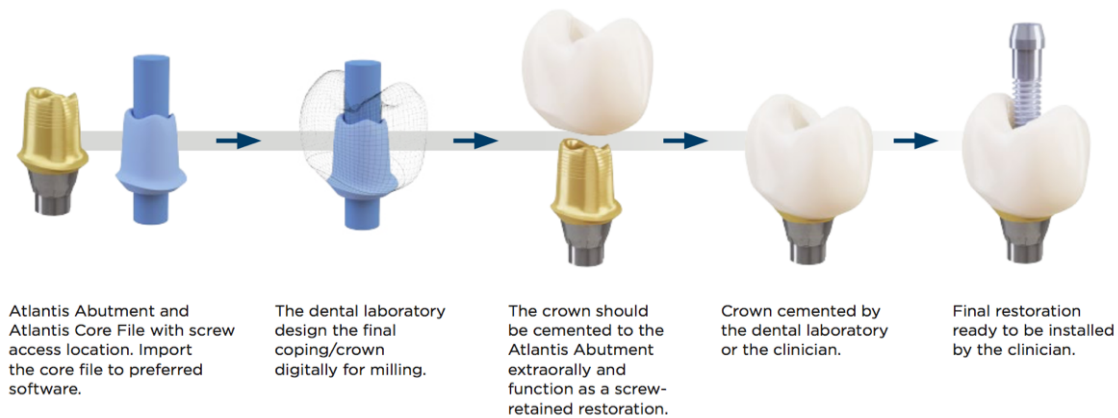
Prosthetic procedure

In order to establish matured soft tissue condition (Berglundh et al., 2007, Salvi et al., 2015) 4 weeks after AC a digital impression with an implant scan-body will be taken. Healing abutments will be re-inserted and left until the try-in of the abutment/crown.



A titanium abutment (Atlantis® Abutment, DentsplySirona Implants, Mölndal, Sweden) will be designed according to the respective soft tissue resulting in a physiological emergence profile and a submucosal location of 1-1.5mm of the future abutment/crown transition. At the time of impression taking patients will be randomized into two groups (A and B).

Every patient will receive two identical CAD/CAM-manufactured titanium abutments (Atlantis® Abutment, Dentsply Implants, Mölndal, Sweden). The respective full-contour zirconia crowns will be designed by the dental technician and will further be extraorally or intraorally cemented.



Group A:

12 subjects will receive a screw-retained single crown. A titanium abutment will be digitally designed by the dental technician and milled (Atlantis® Abutment, DentsplySirona, Mölndal, Sweden). After try-in of the abutment, a milled full-contour zirconia crown will be tried in (temporarily glued to the abutment). If occlusal and interdental contacts as well as form and color are satisfactory, the crown (A-) will be cemented extraorally by the dental technician using a resin cement (Multilink, Ivoclar Vivadent, Solna, Sweden) (Fig.2). Any cement excess will be removed, checked with binoculars and the subgingival part of the reconstruction polished before insertion. The reconstruction will be left in situ for 16 weeks. After the first period of 16 weeks, a new titanium abutment (duplicate) will be milled (Atlantis® Abutment, DentsplySirona, Mölndal, Sweden), allowing for cementation of a single crown. A new full-contour zirconia crown (A+) will be designed (by the dental technician), milled and cemented intraorally again using the same resin cement (Multilink, Ivoclar Vivadent, Solna, Sweden) (Fig.2). After setting of the cement, the seat of the crown as well as the occlusion will be checked. Great care will be given in order to remove any excess

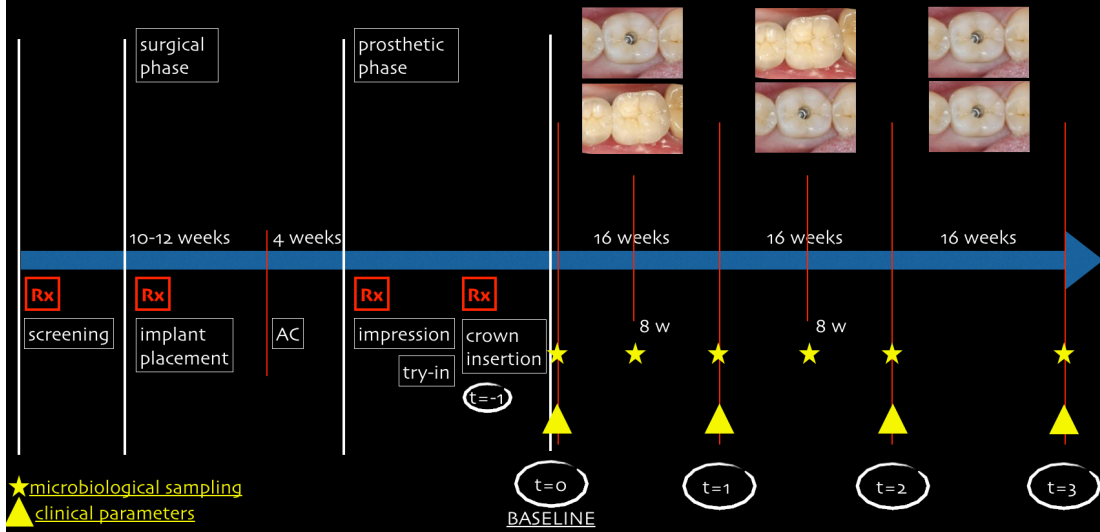
cement. Absence of cement will be verified by taking a single-tooth x-ray. Again, this reconstruction will be followed up every 4 weeks and the reconstruction will be left in situ for a second period of 16 weeks. Subsequently, all patients will be restored with the original screw-retained clinically perfect crown (A-). Hence, group A yields no cement residues in the first period, but may do so in the second time-period (A-/+).

Group B:

12 subjects will undergo the same, but reverse order of therapy:

In the first period the subjects will receive a cement-retained full-contour zirconia crown (B+) on an individualized titanium abutment (Atlantis® Abutment, DentsplySirona, Mölndal, Sweden). Again, great care will be given in order to remove any excess cement. After cementation, a single-tooth x-ray will be taken to control the fit of the crown and the absence of any possible cement residues. In the second period of 16 weeks a new full-contour zirconia crown on an identically designed titanium abutment (Atlantis® Abutment, DentsplySirona, Mölndal, Sweden) will be extraorally cemented and fixed by screw-retention leaving no cement residues (B-). Subsequently, all patients will be fitted with the screw-retained crown (B-).

study overview



Follow up

Clinical parameters

The following clinical indices will be obtained at determined timepoints:

t-1 = at the time of crown insertion

- before crown-insertion:

Mucosa thickness (MT) using a calibrated periodontal probe (UNC 15)

(measuring from the margo mucosae to the crown/abutment conversion)

t0 = 1week after crown insertion (Baseline)

- Probing depth (D) using a calibrated periodontal probe (UNC 15 with a point diameter of 0.4mm) and a probing pressure of approximately 0.25 N
- modified PLI (mPLI) (Mombelli et al., 1988)
- modified Bleeding index (mBI) (Mombelli et al., 1988)
- Microbiological sampling using sterile paper points at four sites per implant

t1 = 8 weeks ($\pm 1w$) after crown insertion

- Microbiological sampling

t2 = before insertion of new crown (at the end of the 1st 16week-period)

- PD
- modified PLI (mPLI) (Mombelli et al., 1988)
- modified Bleeding index (mBI) (Mombelli et al., 1988)
- Recession of the soft tissue using a calibrated periodontal probe (UNC 15)
- Microbiological sampling

t3 = 8 weeks ($\pm 1w$) after insertion crown of second crown

- Microbiological sampling

t4 = before insertion of the final screw-retained crown in all patients

(at the end of the 2nd 16week-period)

- PD
- modified PLI (mPLI) (Mombelli et al., 1988)
- modified Bleeding index (mBI) (Mombelli et al., 1988)
- Recession of the soft tissue using a calibrated periodontal probe (UNC 15)
- Microbiological sampling

t5 = termination of experiment

(after 16 weeks with final screw-retained crown)

- PD
- modified PLI (mPLI) (Mombelli et al., 1988)
- modified Bleeding index (mBI) (Mombelli et al., 1988)
- Recession of the soft tissue using a calibrated periodontal probe (UNC 15)
- Microbiological sampling

Attachment levels will be calculated by deducting recessions (negative) from the probing depths. All patients will be followed up one year after insertion of the screw-retained crowns (t2) for a regular check-up.

Radiographs

A single-tooth x-ray will be obtained at the time of AC to ensure sufficient osseointegration of the implant before entering the prosthetic phase. At the time of insertion of the respective reconstruction in both groups, another periapical radiograph will be obtained to ensure the fit of the reconstruction and to check for eventual cement residue.

Microbiological sampling and analysis

8 weeks after the placement of the first reconstruction ($t=1$) and every (8 ± 1 w) weeks thereafter as well as 16 weeks after insertion of the final screw-retained crown, microbiological samples will be obtained.

Gingival crevicular fluid (GCF) will be collected using standardized filter paper strips (Periopaper®, Harco, Winnipeg, Canada) from the implant site. The site will be first isolated with cotton rolls and air dried. The sterile paper strip is then placed at the entrance of the sulcus (superficial intracrevicular method ([Griffiths, 2003](#)) and left in place for 30s. After that, the strip(s) is (are) placed in a new Eppendorf tube.

Thereafter, sterile paper points will be inserted until resistance is felt at four sites in the peri-implant sulcus. Without removing of supragingival plaque, sterile paper point (ISO 50) will be inserted into the periodontal pocket for 30 s.

Subsequently, the samples will be frozen and sent to the laboratory of oral microbiology at the University of Berne (Prof. Sigrun Eick). A battery of 10 putative periodontal pathogens will be analyzed using real-time PCR. Moreover, the samples will be assayed for host markers such as MMP 8 and IL-1 β using ELISA.

Bleeding on sampling will be obtained at the same time intervals.

Harvesting of biopsies

At the time of insertion of the screw-retained final crown ($t=4$) and in case of a sufficient amount of keratinized mucosa, a crestal full-thickness soft tissue biopsy will be harvested. Two parallel crestal incisions will be connected to sulcular incisions at both the implant and adjacent tooth. The dimensions of the biopsies will be 2 mm in

width and a length ranging from the distal/mesial aspect of the implant site to the mesial/distal aspect of the adjacent tooth. The vertical dimension will be extended from the mucosal margin to the bone crest.

1-2 single sutures will be used to adapt the wound margins and to prevent the exposure of the bone. All patients will be re-instructed to clean the implant sites using 0.2% chlorhexidine rinsing solution. No manual cleaning will be allowed for another 7 days i.e. until suture removal.

The biopsies will be used for histomorphometric measurements as well as the determination of inflammation and/or infection markers applying light-microscopy. Tissue samples will further be processed with a (ribonucleic acid) RNA solution to allow for RNA extraction. This will then be analyzed via polymerase chain reaction (PCR) to extract the inflammation genome and identify inflammation markers such as Interleukin (IL-4, IL-3, IL-1 alpha, IL-1 beta) and tumor necrosis factor (TNF-alpha). A part of these biopsies will further be used for the determination of inflammatory markers using PCR.

Evaluation of cement residues

Retrieved crowns will be examined using light-microscopy/electron microscopy to determine the area of submucosal excess cement.

Statistical analysis

The clinical and microbiological data will be analysed longitudinally with paired t-test testing the hypothesis with no difference between the two timepoints and between groups within the experimental periods of 16 weeks.

- Berglundh, T., Abrahamsson, I., Welander, M., Lang, N. P. & Lindhe, J. (2007) Morphogenesis of the peri-implant mucosa: an experimental study in dogs. *Clinical Oral Implants Research* **18**, 1-8. doi:10.1111/j.1600-0501.2006.01380.x.
- Berglundh, T., Zitzmann, N. U. & Donati, M. (2011) Are peri-implantitis lesions different from periodontitis lesions? *Journal of Clinical Periodontology* **38 Suppl 11**, 188-202. doi:10.1111/j.1600-051X.2010.01672.x.
- Bjorn, A. L., Bjorn, H. & Grkovic, B. (1969) Marginal fit of restorations and its relation to periodontal bone level. I. Metal fillings. *Odontologisk Revy* **20**, 311-321.
- Brunsvold, M. A. & Lane, J. J. (1990) The prevalence of overhanging dental restorations and their relationship to periodontal disease. *Journal of Clinical Periodontology* **17**, 67-72.
- Claman, L. J., Koidis, P. T. & Burch, J. G. (1986) Proximal tooth surface quality and periodontal probing depth. *Journal of the American Dental Association* **113**, 890-893.
- Griffiths, G. S. (2003) Formation, collection and significance of gingival crevice fluid. *Periodontology 2000* **31**, 32-42.
- Haffajee, A. D. & Socransky, S. S. (2005) Microbiology of periodontal diseases: introduction. *Periodontology 2000* **38**, 9-12. doi:10.1111/j.1600-0757.2005.00112.x.
- Heitz-Mayfield, L. J. (2008) Peri-implant diseases: diagnosis and risk indicators. *Journal of Clinical Periodontology* **35**, 292-304. doi:10.1111/j.1600-051X.2008.01275.x.
- Jansson, L., Ehnevid, H., Lindskog, S. & Blomlof, L. (1994) Proximal restorations and periodontal status. *Journal of Clinical Periodontology* **21**, 577-582.
- Jepsen, S., Berglundh, T., Genco, R., Aass, A. M., Demirel, K., Derks, J., Figuero, E., Giovannoli, J. L., Goldstein, M., Lambert, F., Ortiz-Vigon, A., Polyzois, I., Salvi, G. E., Schwarz, F., Serino, G., Tomasi, C. & Zitzmann, N. U. (2015) Primary prevention of peri-implantitis: managing peri-implant mucositis. *Journal of Clinical Periodontology* **42 Suppl 16**, S152-157. doi:10.1111/jcpe.12369.
- Korsch, M., Obst, U. & Walther, W. (2014) Cement-associated peri-implantitis: a retrospective clinical observational study of fixed implant-supported restorations using a methacrylate cement. *Clinical Oral Implants Research* **25**, 797-802. doi:10.1111/clr.12173.
- Lang, N. P., Kiel, R. A. & Anderhalden, K. (1983) Clinical and microbiological effects of subgingival restorations with overhanging or clinically perfect margins. *Journal of Clinical Periodontology* **10**, 563-578.
- Mombelli, A., Buser, D. & Lang, N. P. (1988) Colonization of osseointegrated titanium implants in edentulous patients. Early results. *Oral Microbiology and Immunology* **3**, 113-120.
- Mombelli, A. & Decaillet, F. (2011) The characteristics of biofilms in peri-implant disease. *Journal of Clinical Periodontology* **38 Suppl 11**, 203-213. doi:10.1111/j.1600-051X.2010.01666.x.
- Nassar, U., Meyer, A. E., Ogle, R. E. & Baier, R. E. (1995) The effect of restorative and prosthetic materials on dental plaque. *Periodontology 2000* **8**, 114-124.
- Salvi, G. E., Bosshardt, D. D., Lang, N. P., Abrahamsson, I., Berglundh, T., Lindhe, J., Ivanovski, S. & Donos, N. (2015) Temporal sequence of hard and soft tissue healing around titanium dental implants. *Periodontology 2000* **68**, 135-152. doi:10.1111/prd.12054.

- Serino, G. & Strom, C. (2009) Peri-implantitis in partially edentulous patients: association with inadequate plaque control. *Clinical Oral Implants Research* **20**, 169-174. doi:10.1111/j.1600-0501.2008.01627.x.
- Shahabouee, M., Rismanchian, M., Yaghini, J., Babashahi, A., Badrian, H. & Goroohi, H. (2012) Microflora around teeth and dental implants. *Dent Res J (Isfahan)* **9**, 215-220.
- Staubli, N., Walter, C., Schmidt, J. C., Weiger, R. & Zitzmann, N. U. (2016) Excess cement and the risk of peri-implant disease - a systematic review. *Clinical Oral Implants Research*. doi:10.1111/clr.12954.
- Than, A., Duguid, R. & McKendrick, A. J. (1982) Relationship between restorations and the level of the periodontal attachment. *Journal of Clinical Periodontology* **9**, 193-202.
- Waerhaug, J. (1956) Observations on replanted teeth plated with gold foil; reaction to pure gold; mode of epithelial attachment to gold; expulsion of foreign bodies from pockets. *Oral Surgery, Oral Medicine, Oral Pathology* **9**, 780-791.
- Wilson, T. G., Jr. (2009) The positive relationship between excess cement and peri-implant disease: a prospective clinical endoscopic study. *Journal of Periodontology* **80**, 1388-1392. doi:10.1902/jop.2009.090115.