

The Prevalence of a Second Mesio Buccal Canal of Maxillary First and Second Molars Using CBCT among Egyptian Population: A Cross- Sectional Study

Protocol submitted to the Faculty of Dentistry

Cairo University

**In partial fulfilment of the requirements for Master Degree in
Oral and Maxillofacial Radiology**

Research Code: Rad2:5:1

Clinical Trials.gov ID: NCT03225573

Presented by:

Yomna Mohammad Gamal EL-Din Saadi

Faculty of Dentistry

Misr International University

B.D.S 2012

6 July 2017

Supervisors

Dr. Nashwa Salah

Professor of Oral and Maxillofacial Radiology

Faculty of Dentistry

Cairo University

Dr. Farid Medhat

Lecturer of Oral and Maxillofacial Radiology

Faculty of Dentistry

Cairo University

Introduction

Knowing the proper root and canal morphology is of paramount importance to avoid failures of endodontic treatment. (**Altunsoy *et al* 2014**). Root canal morphology is also important during post-core and crown restorations because post preparation can result in root canal deviation or root canal perforation.

Therefore, clinicians should recognize the common root canal morphologies and possible anatomic variations. The clinician should be aware of the possibility of having additional canals in order to minimize the risk of treatment failure (**Weine *et al* 1969 and Vertucci 2005**).

The internal complexities of root canals are genetically determined and carry definitive importance in anthropology (**Neelakantan *et al* 2010, Silva *et al* 2014**). It is necessary to consider racial differences during clinical treatment.

The Root canal anatomical variations due to genetic and ethnic differences have been discussed in many studies (**Chen & Tong 2004; Weng *et al* 2009; HosseinpourSepanta *et al* 2016 and Naseri *et al* 2016**).

Many studies investigated the morphology of the maxillary permanent molars focusing on the presence of a second mesiobuccal root canal in the mesial root (**Pecora *et al* 1992; Sert & Bayirli 2004; Cleghorn *et al* 2006**). They reported varying prevalence of the second mesiobuccal canal of maxillary first and second molars.

The maxillary molars have a complex morphology (**Silva *et al* 2014**). Based on the published results, it was recognized that most maxillary first molars have 3 roots and 4 canals. Most studies reported prevalence of a second canal (MB2) in the mesiobuccal (MB) root in over 50% of the cases.

Different cross-sectional tomograms, CT and lately, dental cone beam CT (CBCT) examinations have been used to study endodontic anatomy. (**Gahleitner *et al* 2003** and **Kiarudi *et al* 2015**).

Rational of the Study

Prevalence of a second mesiobuccal canal in the mesial root of first and second maxillary molars is not clearly studied in Egyptian population. The prevalence rate will direct the attention of endodontists to its presence and will justify additional investigations to search for it.

Statement of the Problem

A high percentage of treatment failures is due to the impossibility of detecting the presence and location of the secondary mesiobuccal canal (MB2), located in the mesiobuccal root of the 1st maxillary molars and the 2nd maxillary molars (**Blattner et al 2010**), which prevents the correct implementation of biomechanical instrumentation, irrigation and obturation (Fig. 1).

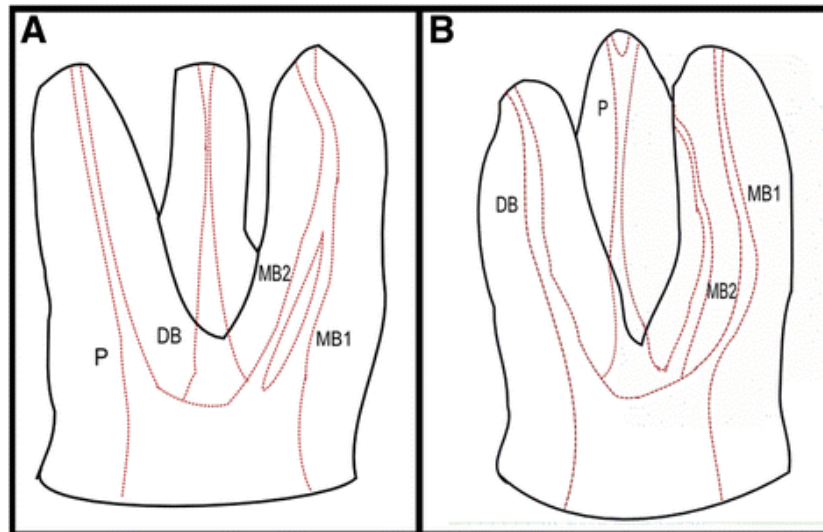


Fig. 1

Maxillary molar with 4 canals: first mesiobuccal canal (MB1), secondary mesiobuccal canal (MB2), distobuccal canal (DB) and palatal canal (P). **A** Maxillary molar with joining mesiobuccal canals. **B** Maxillary molar with two separate mesiobuccal canals (**Betancourt et al 2016**)

Its location in clinical practice is highly complex due to the excessive dentin deposited in the opening of the canal and to the difficulty in visually accessing maxillary molars.

Review of literature

List of main databases used in search:

- Pubmed
- Google Scholar

Keywords:

- Second mesiobuccal canal - CBCT - Prevalence - Population

Maxillary first and second molars have been investigated because of their complex root and canal morphologies (**Calis et al 1995; Ng et al 2001; Alavi et al 2002; Sert & Bayirli 2004; Weng et al 2009; Degerness & Bowles 2010; Neelakantan et al 2010; Zheng et al 2010; Kim et al 2012; Rouhani et al 2014; Silva et al 2014**). According to previous results, most maxillary first molars exhibit 3 roots and 4 canals, including a mesiobuccal root with 2 canals and distobuccal and palatal roots with a single canal each (**Zheng et al 2010; Neelakantan et al 2010; Sert & Baiyrli 2004; Lee et al 2011; Badole 2014**).

Many studies investigated the morphology of the maxillary permanent molars focusing on the presence of a second mesiobuccal root canal in the mesial root (**Pecora et al 1992; Sert & Bayirli 2004; Cleghorn et al 2006; Nikoloudaki et al 2015**). They reported varying prevalence of the second mesiobuccal canal of maxillary first and second molars. **Cleghorn et al 2006** found that the majority of maxillary first molars (95.9%) present 3 roots. The prevalence of a second mesiobuccal root canal in the mesial root varies between 26% (**Pecora 1992**) and 93.5% (**Sert & Bayirli 2004**). **Nikoloudaki et al 2015** attributed these variations to the different methods that were used. The prevalence of two canals in laboratory studies is higher (60.5%) to that reported in clinical studies (54.7%) (**Cleghorn et al 2006**). From the previous studies, **Nikoloudaki et al 2015** concluded that the incidence of the second canal (MB2) in the mesial root is higher than 50%. **Ferguson et al 2005** report the presence of a third canal in the mesial root. **Christie**

et al 1991 in a retrospective study reported a second canal in the palatal root. **Badole et al 2012** found two individual palatal roots (mesiopalatal and distopalatal) with their own separate canals in one case. **Tian et al 2016** found additional canals in first and second molars in a Chinese Population using CBCT in 67.8% and 29.7% of mesiobuccal roots. They found also that the mesiobuccal root canal number showed bilateral symmetry between 79% of first molars and 82.3% of second molars, with a concurrence rate of 59.8% between adjacent molars.

Methods used to evaluate the inner morphology of a root:

Numerous methods have been used to examine root and canal morphologies, including:

- Histologic sections
- Canal staining and tooth clearing (**Ng et al 2001**)
- Sectioning (**Weine et al 1969**)
- Conventional and digital radiography (**Pattanshetti et al 2008, Silva et al 2014**)
- In vitro macroscopic examination (ex vivo using extracted teeth)
- Root canal treatment with magnification (**Zheng et al 2010**)
- The modified canal staining and clearing technique (**Weng et al 2009**)
- Computed tomographic imaging
- Contrast medium–enhanced digital radiography (**Neelakantan et al 2010-2**)
- Cone-beam computed tomographic (CBCT) imaging (**Neelakantan et al 2010, Kim et al 2012 and Rouhani et al 2014**).

Baratto Filho et al 2009 used three methods to evaluate the root canal morphology in maxillary first molars which are ex vivo, clinical, and cone beam computed tomography (CBCT) analysis and found that CBCT imaging was a useful diagnostic tool for this purpose as it can be used as a good method for initial identification of maxillary first molar internal morphology. It is also a non-

destructive tool which offers a higher spatial resolution at lower effective radiation doses and lower costs compared with computed tomographic imaging. In addition it provides a 3 dimensional images of root canal morphology assessment.

In vitro methodologies include various sectioning techniques (sectioning of the root perpendicular or vertically to the long axis of the tooth), root canal impression using low viscosity resin (**Carns et al 1973**), root canal staining, and tooth clearing as described by **Vertucci 1984 and Barker et al 1969**. A main drawback of these techniques is that the samples are irreversibly destructed, thus the results cannot be reproduced.

Clinical studies can evaluate the incidence of additional canals under magnification using loupes or dental operating microscope and by analyzing clinical patients' records or previously treated teeth (**Stropko 1999**). The above-mentioned techniques are unable to reveal in detail the irregularities of the root canal system owing to their inherent limitations. Information gained by peri-apical radiographic images are limited due to superimposition of adjacent teeth and hard tissues of the oro-facial region. Three-dimensional anatomic irregularities can be missed due to the two-dimensional depicting potential and the possible geometric distortion of the image (**Patel et al 2007 and Cotton et al 2007**).

Cone beam-computed tomography (CBCT) imaging techniques offer an effective way to overcome the above limitations .This is feasible by constructing detailed three-dimensional images of the teeth and the surrounding dental and alveolar structures. This information may be utilized for planning and intra-operative guidance (**Nikoloudaki et al 2015**).

Many studies analyzed the anatomic variations of maxillary molars using CBCT technology. **Nikoloudaki et al 2015** reported on the root and canal configurations of maxillary permanent molars in Greek population. In addition, several articles have used cone beam computed tomography (CBCT) to study the

morphology of the maxillary molars and to ascertain its ability to visualize the second mesiobuccal canal (MB2). **Betancourt et al 2016** have examined the geometric location in depth. They described in vivo the prevalence and location of the MB2 in the mesiobuccal root of the first maxillary molar (1MM) and the second maxillary molar (2MM) through CBCT imaging. In the 1MM protocol, the prevalence of the MB2 canal was 69.82% and was more frequent in women ($p = 0.005$). They concluded that CBCT is a high-precision diagnostic tool for not only detecting but also locating in vivo the MB2 canal in the mesiobuccal root of upper molars.

Aim of the Study

The aim of the study is to estimate the prevalence of a second mesiobuccal canal of maxillary first and second molars in Egyptian population.

Population: Egyptian population

Outcome Variable: Presence or absence of a second mesiobuccal canal of maxillary first and second molars

	Outcome Measured	Measuring Device	Measuring Unit
Primary Outcome	Presence of a second mesiobuccal canal of maxillary first and second molars	CBCT Software (On Demand 3D®)	Binary System (Yes/No)
Secondary Outcome	Prevalence in the whole sample (females and males)		Percentage

Research question:

What is the percentage of presence of a second mesiobuccal canal in Maxillary First and Second Molars among Egyptian Population?

Materials and Methods

Study Design: Cross-sectional Study

Setting and Location:

- 1- The data collection will be obtained from the data base available at a private radiographic centre ORASCAN Oral & Maxillofacial Imaging Centre located in Cairo, Egypt.
- 2- CBCT images will be obtained from Egyptian patients who had CBCT examination as part of their dental examination, diagnosis or treatment planning during the years 2015-16-17.

Participants:

A total of 196 CBCT scans of Maxillary first and second permanent molars belonging to Egyptian individuals will be included.

Images of the first and second maxillary permanent molars are selected according to the following **Inclusion criteria:**

- First and second maxillary permanent molars of Egyptian patients starting from 15 years, males or females
- Intact roots without fractures or cracks
- Molars without posts or previous root canal treatment
- CBCT scans of maxillary first and second molars using 8×6 FOV, 0.2 voxel resolution

Exclusion criteria:

- Evidence of apicectomy or periapical surgery
- Odontogenic or non-odontogenic pathology
- Maxillary molars with developmental anomalies

- External or Internal Root resorption
- Canal Calcification
- Previous root canal treatment
- Extensive coronal restorations
- Posts or crown restorations
- Root caries specially reaching the trifurcation area
- Tomographic images of poor quality or artifacts interfering with the detection of root canals

Variables:

1. Number of root canals in mesiobuccal root of first and second maxillary molars
2. Sex of the patient will be identified and addressed as the prevalence of the second mesiobuccal canal may show sex predilection

Data Sources / Measurements:

Retrospective Data Analysis will be performed after the CBCT images are pooled from the computer database.

All the CBCT examinations were scanned using Cranex[®] 3D SOREDEX, 0.2 voxel resolution, 8 × 6 cm FOV, 90 kVp, 10 mA and 6 seconds exposure time.

CBCT images will be analysed in the 3 planes; first the sagittal and coronal sections will be oriented parallel to the long axis of the root, and then sections will be obtained on the axial plane for detection of the 2nd mesiobuccal canal **(Betancourt et al 2016).**

CBCT images will be interpreted by three oral radiologists independently; blinded from demographic data of the patients and from the results of each other.

Each one will evaluate the images separately twice with a period of two weeks between the two reading sessions.

Then inter-observational and intra-observational variability between the observers will be evaluated.

The sex of the patient will be identified from the patient's demographic data available on the patient's file on the database of the private radiographic centre.

Bias:

No source of bias.

Study Size:

The aim of the study is to assess the prevalence of a second mesiobuccal canal of maxillary first and second molars in Egyptian population. Based on the previous paper by Nikoloudaki et al, 2015, the prevalence of Second Mesiobuccal Canal of Maxillary First and Second Molars was 89 and 85%. Using a precision of 5, a design effect set at 1 with 95% CI (confidence interval), a total sample size of 196 will be sufficient. The sample size was calculated by Epi info.

Sampling Strategy: The sample will be collected by simple random sampling.

Quantitative Variables:

The number of CBCT scans of Egyptian individuals with second mesiobuccal canal will be counted to estimate the prevalence of the second mesiobuccal canal.

Statistical Methods:

1- Data will be analysed using IBM SPSS advanced statistics (Statistical Package for Social Sciences), version 21 (SPSS Inc., Chicago, IL). Numerical data will be described as mean and standard deviation or median and range. Categorical data will be described as numbers and percentages. Comparisons between male and females for normally distributed numeric variables will be done using the Student's t-test while for non-normally distributed numeric variables will be done by Mann-Whitney test. Comparisons between categorical variables will be performed using the chi square test. A p-value less than or equal to 0.05 will be considered statistically significant. All tests will be two tailed.

2- If the patient's age couldn't be found in the patient's file, the dental age will be used.

3- If the patient's sex couldn't be found in the patient's file, the patient's name will be used to indicate the sex. Patients with mixed name will be excluded.

References

1. Alavi AM, Opasanon A, Ng YL, et al. Root and canal morphology of Thai maxillary molars. *Int Endod J* 2002; 35:478–85.
2. Altunsoy M, Ok E, Nur BG, Aglarci OS, Gungor E, Colak M. Root canal morphology analysis of maxillary permanent first and second molars in a southeastern Turkish population using cone-beam computed tomography. *Journal of Dental Sciences*. 2014; 10(4):401-7.
3. Badole GP, Bahadure RN, Warhadpande MM, Kubde R. A rare root canal configuration of maxillary second molar: a case report. *Case Rep Dent* 2012; 2012: 767582.
4. Badole GP, Warhadpande MM, Shenoi PR, et al. A rare root canal configuration of bilateral maxillary first molar with 7 root canals diagnosed using cone-beam computed tomographic scanning: a case report. *J Endod* 2014; 40:296–301.
5. Baratto Filho F, Zaitter S, Haragushiku GA, et al. Analysis of the internal anatomy of maxillary first molars by using different methods. *J Endod* 2009; 35:337–42.
6. Barker BCW, Lockett BC, Parsons KC. The demonstrations of root canal anatomy. *Aust Dent J* 1969; 14: 37-41
7. Betancourt P, Navarro P, Muñoz G, Fuentes R. Prevalence and location of the secondary mesiobuccal canal in 1,100 maxillary molars using cone beam computed tomography. *BMC Medical Imaging* 2016; 16:66
8. Blattner T, George N, Lee C, Kumar V, Yelton C. Efficacy of Cone-Beam Computed Tomography as a Modality to Accurately Identify the Presence of Second Mesiobuccal Canals in Maxillary First and Second Molars: A Pilot Study. *J Endod*. 2010; 36:867–70.

9. Caliskan MK, Pehlivan Y, Sepetci IO, Guler F, et al. Root canal morphology of human permanent teeth in a Turkish population. J Endod 1995; 21:200–4.
10. Carns EJ, Skidmore AE, Morgantown W. Configurations and deviations of root canals of maxillary first premolars. Oral Surg 1973; 36: 880-6.
11. Chen G YH, Tong C. Investigation of the root canal configuration of mandibular first molars in a Taiwan Chinese population. Int Endod J. 2009; 42(11):1044–9.
12. Christie WH, Pekoff MD, Fugel HM. Maxillary molar with two palatal root a retrospective clinical study. J Endod 1991; 17: 80-4.
13. Cleghorn BM, Christie WH, Dong CC. Root and root canal morphology of the human permanent maxillary first molar: a literature review. J Endod 2006; 32: 813-21.
14. Cotton TP, Geisler TM, Holden DT, Schwartz SA, Schindler WG. Endodontic applications of cone beam volumetric tomography. J Endod 2007; 33: 1121-32.
15. Degerness RA, Bowles WR. Dimension, anatomy and morphology of the mesiobuccal root canal system in maxillary molars. J Endod 2010; 36:985–9.
16. Ferguson DB, Kjar KS, Hartwell GR. Three canals in the mesiobuccal root of a maxillary first molar: a case report. J Endod 2005; 31: 400-2.
17. Gahleitner A, Watzek G, Imhof H. Dental CT: imaging technique, anatomy and pathologic conditions of the jaws. Eur Radiol 2003; 13: 366–376
18. HosseinpourSepanta KJ, KhayatAkbar, Naseri Mandana. Root Canal Morphology of Permanent Mandibular Premolars in Iranian Population: A Systematic Review. Iran Endod J. 2016 11(3):150-6.

19. Kiarudi AH, Eghbal MJ, Safi Y, Aghdasi MM, Fazlyab M. The applications of cone-beam computed tomography in endodontics: a review of literature. *Iran Endod J.* 2015; 10(1):16-25.
20. Kim Y, Lee SJ, Woo J. Morphology of maxillary first and second molars analyzed by cone-beam computed tomography in a Korean population: variations in the number of roots and canals and the incidence of fusion. *J Endod* 2012; 38:1063–8.
21. Lee JH, Kim KD, Lee JK, et al. Mesio Buccal root canal anatomy of Korean maxillary first and second molars by cone-beam computed tomography. *Oral Surg Oral Med Oral Pathol Oral Radiol Endod* 2011; 111:785–91.
22. Neelakantan P, Subbarao C, Ahuja R, et al. Cone-beam computed tomography study of root and canal morphology of maxillary first and second molars in an Indian population. *J Endod* 2010; 36:1622–7.
23. Neelakantan P, Subbarao C, Subbarao CV. Comparative evaluation of modified canal staining and clearing technique, cone-beam computed tomography, peripheral quantitative computed tomography, spiral computed tomography, and plain and contrast medium-enhanced digital radiography in studying root canal morphology. *J Endod* 2010; 36:1547–51.
24. Ng YL, Aung TH, Alavi A, et al. Root and canal morphology of Burmese maxillary molars. *Int Endod J* 2001; 34:620–30.
25. Nikoloudaki GE, Kontogiannis TG and Kerezoudis NP. Evaluation of the root and canal morphology of maxillary permanent molars and the incidence of the second mesio Buccal root canal in Greek population using cone-beam computed tomography. *The Open Dentistry Journal* 2015; 9 (2): 267-72.

26. Patel S, Dawood A, Pitt Ford T, Whaites E. The potential applications of cone beam computed tomography in the management of endodontic problems. *Int Endod J* 2007; 40: 818-30.
27. Pattanshetti N, Gaidhane M, Al Kandari AM. Root and canal morphology of the mesiobuccal and distal roots of permanent first molars in a Kuwait population—a clinical study. *Int Endod J* 2008; 41:755–62.
28. Pecora JD, Woelfel JB, Sousa Neto MD, Issa IP. Morphologic study of the maxillary molars. Part II: internal anatomy. *Braz Dent J* 1992; 3: 53-7.
29. Rouhani A, Bagherpour A, Akbari M, et al. Cone-beam computed tomography evaluation of maxillary first and second molars in Iranian population: a morphological study. *Iran Endod J* 2014; 9:190–4.
30. Sert S BG. Evaluation of the root canal configurations of the mandibular and maxillary permanent teeth by gender in the Turkish population. *J Endod.* 2004; 30(6):391-8.
31. Sert S, Bayirli GS. Evaluation of the root canal configurations of the mandibular and maxillary permanent teeth by gender in the Turkish population. *J Endod* 2004; 30: 391-8.
32. Silva EJ, Nejaim Y, Silva AI, Haiter-Neto F, Zaia AA, Cohenca N. Evaluation of root canal configuration of maxillary molars in a Brazilian population using cone-beam computed tomographic imaging: an in vivo study. *J Endod.* 2014; 40(2):173-6.
33. Stropko JJ. Canal morphology of maxillary molars: clinical observations of canal configurations. *J Endod* 1999; 25: 446-50.
34. Tian X, ,Yang X, Qian L, Wei B, Gong Y. Analysis of the Root and Canal Morphologies in Maxillary First and Second Molars in a Chinese Population Using Cone-beam Computed Tomography. *J Endod* 2016; -:1–6
35. Vertucci FJ. Root canal anatomy of the human permanent teeth. *Oral Surg Oral Med Oral Pathol* 1984; 58: 589-99.

36. Vertucci FJ. Root canal morphology and its relationship to endodontic procedures. *Endod Top* 2005; 10: 3-29.
37. Weine FS, Healey HJ, Gerstein H, Evanson L. Canal configuration in the mesiobuccal root of the maxillary first molar and its endodontic significance. *Oral Surg Oral Med Oral Pathol* 1969; 28: 419
38. Weine FS. *Endodontic Therapy*. 4th ed. St. Louis, MO: Mosby 1989; pp. 222-3.
39. Weng XL, YS, Zhao SL, et al. Root canal morphology of permanent maxillary teeth in the Han nationality in Chinese Guanzhong area: a new modified root canal staining technique. *J Endod*. 2009; 35:651-6
40. Zheng QH, Wang Y, Zhou XD, et al. A cone-beam computed tomography study of maxillary first permanent molar root and canal morphology in a Chinese population. *J Endod* 2010; 36:1480–4.