2025

Clinical Trial Protocol

NCT : NOT YET AVAILABLE DATE: 29/6/2025

Clinical evaluation of resin based versus giomer fissure sealants on MIH affected permanent molars (RCT)

Introduction

The term molar incisor hypomineralisation (MIH) was suggested by Weerheijm *et al* in 2001 and he defined it as a congenital and qualitative enamel defect of systemic origin of one to four permanent first molars, frequently associated with affected incisors **(Weerheijm *et al.*, 2001).**

The condition was attributed to disrupted ameloblastic function during the transitional and maturational stages of amelogenesis. (Fearne *et al*., 2004). The defect was presumed to be the result of a variety of environmental factors acting systemically, including prenatal, perinatal and childhood medical conditions that affect the developing enamel, while an underlying genetic predisposition could not be excluded **(Lygidakis *et al*., 2008).**

The disorder is clinically characterized by well-demarcated opacities of varying severity, including the color and extension of the lesion. The defected areas demonstrate lower mineral density and elevated protein/water content, increased porosity, disorganized enamel crystals and enlarged inter-prismatic spaces **(Crombie *et al.,* 2013).**

MIH is becoming an important public health issue with global prevalence of 12.9%–14.2% being reported. Prevalence of MIH appeared to be increasing, and managing affected children is now a common problem for pediatric dentists. However, these figures may be an underestimation as the exact prevalence of MIH is not known due to the use of different indexes and diagnostic criteria **(Lygidakis *et al*., 2021)**.

A cross-sectional study in Egypt, a total of 371 children aged 8-12 from the Giza governorate were screened for the presence of MIH and its severity. Results revealed that the prevalence of MIH was 2.7%. MIH occurred more in the mandible than in the maxilla and in molars teeth more than incisors teeth. In addition, the most prevalent defect reported in this study was demarcated opacity and the most common degree of severity of MIH was the mild degree. Regular follow-up and recall program for children affected with MIH for the application of the appropriate preventive and therapeutic measures was recommended. There was also a recommendation for formulating public awareness and preventive programs for MIH **(Aya Refaat Abd El Ghaffar *et al.*, 2022).**

MIH increases dental caries risk of affected teeth because teeth not only have soft and porous enamel but are also very sensitive to stimuli making effective oral hygiene difficult **(Crombie *et al*., 2009)**.

Early Prevention and early identification of MIH affected teeth is key to the management of affected molars. In addition, enhanced oral hygiene instruction and dietary advice should be provided and reinforced regularly to both children and their carers **(Fragelli *et al*., 2015).** It has been reported that MIH patients had higher caries experience with increased need and frequency of dental treatment. Since MIH poses a high caries risk, an intensive preventive approach should be planned as soon as the lesions are diagnosed on the erupting FPMs **(Americano *et al.*, 2017)**

It had been reported that of MIH-affected teeth, 27.4% (23.5–31.7%) did require the need for treatment due to pain, sensitivity, or post-eruptive breakdown. There were several available treatment options for both MIH-affected molars and incisors. Modalities ranged from prevention, restoration to extraction and possible post-extraction orthodontic treatment. However, deciding which approach is appropriate is complex **(Schwendicke *et al.,* 2018).**

For fully erupted MIH affected molars, resin-based fissure sealants should be considered the first line approach in preventing both dental caries and post-eruptive breakdown **(Fragelli *et al.,* 2017)**.

According to systematic review by **Somani *et al.,* 2022**, There was convincing evidence to support the use of resin-based fissure sealants, preformed metal crowns, direct composite resin restorations and laboratory-made restorations for MIH-affected molars in specific clinical scenarios. There was a recommendation for further high-quality studies with more participants, longer follow up periods and more clinically relevant and appropriate outcome measures in the management of MIH-affected teeth.

Regarding the treatment of MIH, future research focused on further improvements in adhesion, the use of new materials and the assessment of novel more minimally invasive techniques. Furthermore, to address the psychosocial and economic impacts of MIH treatments, a holistic management strategy should be adopted **(Lygidakis *et al.*, 2021).**

The adhesion of resin materials to hypomineralized enamel were significantly lower than unaffected teeth **(Kotsanos *et al.*, 2005).**

A clinical study by **Lygidakis *et al.,* 2009** showed that 21% of the resin sealants, which were placed with conventional technique (etch and rinse+ resin sealant application) with prior mechanical preparation, were lost (partially or total) 12 months after placement. On the other hand, a higher retention rate was achieved after four years by using a 5th generation bonding agent as an intermediate layer.

The use of an adhesive during fissure sealant placement was advised as it had been clearly shown to increase the retention rate **(Lygidakis *et al*., 2009).**

Fagrelli *et al.,* 2010 reported that acid etching of the hypomineralized enamel in resin-based sealants exposes the organic part of the prism sheaths, which may affect the properties of the restorative material. A new hybrid material (Giomer) that combined the advantages of resin composites with glass ionomer cements had been introduced. As Giomer contains S-PRG (surface pre-reacted glass) filler and bonded by self-etch primer, it had been shown to prevent demineralization, microleakage and gap formation. Also, can maintain the enamel surface integrity without the tags created by acid etching **(Shimazu *et al*., 2012).**

The self-etch adhesive systems had been recommended in children as they require fewer treatment steps and decrease the patient-related technique sensitivity. However, their bonding efficacy was much controversial even for unground sound enamel, since most of these agents are not as acidic as phosphoric acid **(Feigal and Donly, 2006).**

Fragelli *et al*., 2017 compared the survival rates of resin sealants applied to the sound and MIH-affected molars without mechanical preparation or adhesive application. After 1 year, the authors reported 37.4% and 24% sealant loss for sound and hypomineralized teeth, respectively. They related their findings to possible remineralization of teeth which was achieved by four-time weekly application of fluoride varnish prior to the treatment.

The literature is very limited about the use of sealants on MIH-affected teeth and more clinical trials are required to identify appropriate restorative alternatives **(Özgür et al., 2022).** Therefore, this study aims to evaluate the clinical success of giomer and conventional resin-based sealants applied on first permanent molars (FPMs) affected by MIH.

Aim of the study

1. Evaluate the clinical success rates of conventional resin-based and giomer-based sealants on MIH-affected first permanent molars.
2. Corelate between the clinical features of the MIH lesions (color and extension) and clinical success rates of the sealants used.

Subjects and Methods

Study design

Randomized clinical trial that will be conducted in the outpatient clinic of dentistry, Excellence hospital, National Research Centre.

Sample size calculation

Based on Özgür et al (2022) [1] and Using G power statistical power Analysis program (version 3.1.9.4) for sample size determination[2], A total sample size (n=22; 11 in each group, will be sufficient to detect a large effect size (d) = 1.66, with an actual power (1-β error) of 0.95 (95%) and a significance level (α error) 0.05 (5%) for two-sided hypothesis test.

- **Eligibility criteria**

Inclusion criteria

- Apparently Healthy Children aged 6-12 years having at least one fully erupted First Permanent Molar (FPM) with MIH indicated for non-invasive fissure sealant.
- Cooperative children.
- Occlusal mild MIH defects (demarcated white, yellow or brown lesions)
- sound surfaces and no incipient enamel caries, where moist control can be achieved.

Exclusion criteria

- Children having hypomineralized FPMs with post eruption breakdown (PEB).
- Cavitated carious lesions.
- Restorations, fixed orthodontic appliances.
- Enamel defect(s) due to a condition other than MIH.

Clinical examination

An informed consent will be obtained from parents.

All children will be examined under the same dental setting that includes a standard light source using a metallic mirror by single investigator.

The 4 first permanent molars and 8 permanent incisors will be examined wet after cleaning using cotton rolls for demarcated opacities. Diagnosis of MIH will be made according to the European Academy of Paediatric Dentistry (EAPD) criteria **(Weerheijm *et al*., 2003)**. Demarcated opacity is a demarcated defect involving an alteration in the translucency of the enamel, variable in degree. The defective enamel is of normal thickness with a smooth surface and can be white, yellow or brown in color. The localization (buccal, lingual/palatal, occlusal) and the color (white, yellow, brown) of the opacities will be recorded in a Data collection form for lesion characteristics in order to evaluate their effects on fissure sealant success.

The Modifed United States Public Health Service (USPHS) criteria will be used for follow-up evaluations of the fissure sealants at 6 and 12 months.

Clinical procedures

- **Randomization, allocation and grouping:**

  Children who will be included in this trial will be randomly distributed by an investigator with no clinical involvement in the trial **(Doig and Simpson, 2005)** in one of two groups (simple randomization 1:1 allocation ratio) through:

  Sequence generation: by using Rondom.org. online software.

  Allocation concealment: 1:1 allocation ratio done using opaque envelop.

  Patients grouping: two parallel groups

  - Group 1: Resin based sealant (Fisseal, Promedica , Germany).
  - Group 2: Giomer based sealant (BeautiSealant, Shofu, Japan).

Molars will be Cleaned with a bristle brush and a non-fluoridated paste operated by a slow speed hand-piece. Then isolation using cotton rolls.

In Group 1 the occlusal surfaces will be etched with 37% phosphoric acid for 30 seconds, rinsed with air–water spray for 30 s and dried with air for 15 s. resin sealant (Fisseal) then applied into the occlusal fissures and light-cured for 20 s.

In Group 2 the self-etch primer (BeautiSealant Primer) will be applied to the occlusal fissures with a fine micro brush. After waiting for 5 s, and homogenizing the bond layer with gentle air stream for 5 s, the giomer sealant (BeautiSealant Paste) will be placed and light-cured for 20 s.

In both groups, the surfaces will be checked with an explorer to ensure that no voids present. The occlusion will be checked and adjusted.

Regular oral hygiene instructions will be given for all patients.

Follow up

Two blinded examiners will assess anatomic form, marginal adaptation, surface texture, marginal discoloration, retention and secondary caries at 1, 3, 6 and 12 months using the modified United States Public Health Service (USPHS) criteria **(Cvar and Ryge, 2005).**

At each recall, teeth will be isolated with cotton rolls and air-dried. Fissure sealants will be checked under artificial light with a dental mirror and straight explorer. The sealants that will receive "Alpha" or "Bravo" scores from all of the USPHS Criteria (anatomic form, marginal adaptation, surface texture, marginal discoloration, retention and secondary caries) will be classified as successful. On the other hand, "Charlie" score from one or more of the USPHS criteria will be considered as a failure and these sealants and will be excluded from further assessment after replacement of the sealant with the conventional technique (etch-and rinse, resin sealant application). The regular clinical follow-ups of all patients will be continued and oral hygiene instructions will be given at every recall.

Blinding: Assessors and statistical analysts will be blinded

This study will be self-funded.

- **Statistical analysis:**

Statistical analysis will be performed using a commercially available software program (SPSS Chicago, IL, USA).

Numerical data will be described as frequencies and percentages. Data will be compared using chi square test. The level of significance will be set at $P \leq 0.05$. All tests will be two tailed.

References

Feigal RJ, Donly KJ. The use of pit and fissure sealants. Pediatr Dent. 2006;28(2):143–50 (discussion 92-8).

20. Shimazu K, Ogata K, Karibe H. Caries-preventive efect of fssure sealant containing surface reaction-type pre-reacted glass ionomer fller and bonded by self-etching primer. J Clin Pediatr Dent. 2012;36(4):343–7. https://doi.org/10.17796/jcpd.36.4.n444r730r773un53

Fragelli CMB, Souza JF, Bussaneli DG, Jeremias F, Santos-Pinto LD, Cordeiro RCL. Survival of sealants in molars afected by molar-incisor hypomineralization: 18-month follow-up. Braz Oral Res. 2017;31: e30. https://doi.org/ 10.1590/1807-3107BOR-2017.vol31.0030.

Özgür, B., Kargın, S.T. & Ölmez, M.S. Clinical evaluation of giomer- and resin-based fissure sealants on permanent molars affected by molar-incisor hypomineralization: a randomized clinical trial. *BMC Oral Health* **22**, 275 (2022). https://doi.org/10.1186/s12903-022-02298-9

Shimazu K, Ogata K, Karibe H. Caries-preventive efect of fssure sealant containing surface reaction-type pre-reacted glass ionomer fller and bonded by self-etching primer. J Clin Pediatr Dent. 2012;36(4):343–7. https://doi.org/10.17796/jcpd.36.4.n444r730r773un53.

Kotsanos N, Kaklamanos EG, Arapostathis K. Treatment management of frst permanent molars in children with Molar-Incisor Hypomineralisation. Eur J Paediatr Dent. 2005;6(4):179–84.

Americano GC, Jacobsen PE, Soviero VM, Haubek D. A systematic review on the association between molar incisor hypomineralization and dental caries. Int J Paediatr Dent. 2017;27(1):11–21. https://doi.org/10.1111/ipd. 12233.

Lygidakis NA, Dimou G, Marinou D. Molar-Incisor-Hypomineralisation (MIH). A retrospective clinical study in Greek children. II. Possible medical aetiological factors. Eur Archs Paediatr Dent. 2008b; 9(4):207-17

Fagrell TG, Dietz W, Jalevik B, Noren JG. Chemical, mechanical and morphological properties of hypomineralized enamel of permanent frst molars. Acta Odontol Scand. 2010;68(4):215–22. https://doi.org/10.3109/ 00016351003752395.

Lygidakis NA, Dimou G, Stamataki E. Retention of fssure sealants using two diferent methods of application in teeth with hypomineralised molars (MIH): a 4 year clinical study. Eur Arch Paediatr Dent. 2009;10(4):223–6. https://doi.org/10.1007/BF03262686.

Crombie FA, Manton DJ, Palamara JE, Zalizniak I, Cochrane NJ, Reynolds EC. Characterisation of developmentally hypomineralised human enamel. J Dent. 2013;41(7):611–8. https://doi.org/10.1016/j.jdent.2013.05. 002

Weerheijm KL, Jalevik B, Alaluusua S. Molar-incisor hypomineralisation. Caries Res. 2001;35(5):390–1. https://doi.org/10.1159/000047479.

Cvar JF, Ryge G. Reprint of criteria for the clinical evaluation of dental restorative materials. Clin Oral Investig. 2005;9(4):215–32. https://doi.org/ 10.1007/s00784-005-0018-z.

Schwendicke F, Elhennawy K, Reda S, Bekes K, Manton DJ, Krois J. Global Burden of Molar Incisor Hypomineralization. 2018;68:10–8.

Crombie, F., Manton, D., & Kilpatrick, N. (2009). Aetiology of molar-incisor hypomineralization: A critical review. In International Journal of Paediatric Dentistry(Vol. 19, Issue 2, pp. 73–83). John Wiley & Sons, Ltd. https://doi.org/10.1111/j.1365-263X.2008.00966.x

C. Somani1 · G. D. Taylor2 · E. Garot3 · P. Rouas3 · N. A. Lygidakis4 · F. S. L. Wong1. An update of treatment modalities in children and adolescents with teeth afected by molar incisor hypomineralisation (MIH): a systematic review. European Archives of Paediatric Dentistry (2022) 23:39–64 https://doi.org/10.1007/s40368-021-00635-0)

Aya Refaat Abd El Ghaffar* , Sara Ahmed Mahmoud** and Marwa Aly Fouad. PREVALENCE OF MOLAR INCISOR HYPOMINERLIZATION AMONG A GROUP OF EGYPTIAN CHILDREN: A CROSS-SECTIONAL STUDY. E.D.J. Vol. 68, No.1. Vol. 68, 29:37, January, 2022. Pages 29:37.

N. A. Lygidakis1 · E. Garot2,3,4 · C. Somani5 · G. D. Taylor6 · P. Rouas2,3,4 · F. S. L. Wong5. Best clinical practice guidance for clinicians dealing with children presenting with molar-incisor-hypomineralisation (MIH): an updated European Academy of Paediatric Dentistry policy document. European Archives of Paediatric Dentistry. Received: 12 September 2021 / Accepted: 22 September 2021. European Archives of Paediatric Dentistry https://doi.org/10.1007/s40368-021-00668-5)

Bullio Fragelli CM, Jeremias F, Feltrin de Souza J, Paschoal MA, de Cassia Loiola CR, Santos-Pinto L. Longitudinal evaluation of the structural integrity of teeth afected by molar incisor hypomineralisation. Caries Res. 2015;49(4):378–83. https://doi.org/10.1159/000380858

Fragelli CMB, Souza JF, Bussaneli DG, Jeremias F, Santos-Pinto LD, Cordeiro RCL. Survival of sealants in molars afected by molar-incisor hypomineralization: 18-month follow-up. Braz Oral Res.

. Lygidakis NA, Dimou G, Stamataki E. Retention of fssure sealants using two diferent methods of application in teeth with hypomineralised molars (MIH): a 4 year clinical study. Eur Arch Paediatr Dent. 2009;10(4):223–6. https://doi.org/10.1007/BF03262686.

(Fearne J, Anderson P, Davis GR. 3D X-ray microscopic study of the extent of variations in enamel density in first permanent molars with idiopathic enamel hypomineralization. Br Dent J 2004;196:634-638)

. Weerheijm KL, Duggal M, Mejare I, Papagiannoulis L, Koch G, Martens LC, et al. Judgement criteria for molar incisor hypomineralisation (MIH) in epidemiologic studies: a summary of the European meeting on MIH held in Athens, 2003. Eur J Paediatr Dent. 2003;4(3):110–3.

Doig GS, Simpson F. Randomization and allocation concealment: a practical guide for researchers. J Crit Care. 2005;20(2):187–91. https://doi.org/ 10.1016/j.jcrc.2005.04.005 (discussion 91-3).

Attachment 2

Tooth Number ……	White Lesion	Yellow Lesion	Brown Lesion
Buccal	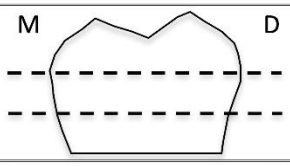	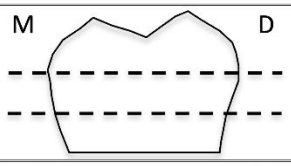	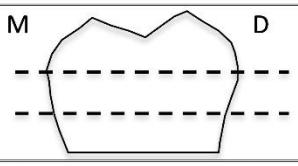
Lingual Palatal	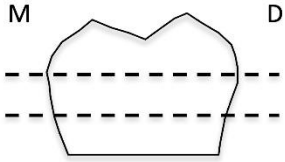	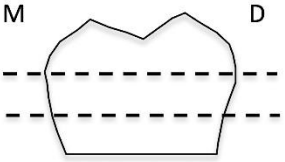	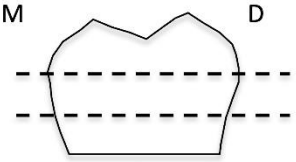
Occlusal	